

ADVANCES IN CARDIOLOGY, INTERVENTIONAL CARDIOLOGY, AND CARDIOTHORACIC SURGERY



COLUMBIA UNIVERSITY

College of Physicians
and Surgeons



Weill Cornell
Medicine

Adult Congenital Heart Disease Comes of Age

Emile A. Bacha, MD

Chief, Division of Cardiac,
Thoracic and Vascular Surgery
NewYork-Presbyterian/
Columbia University Medical Center
Director, Congenital and
Pediatric Cardiac Surgery
NewYork-Presbyterian Hospital
eb2709@cumc.columbia.edu

Leonard N. Girardi, MD

Cardiothoracic Surgeon-in-Chief
NewYork-Presbyterian/
Weill Cornell Medical Center
lngirard@med.cornell.edu

Bruce B. Lerman, MD

Chief, Maurice R. and Corinne P.
Greenberg Division of Cardiology
NewYork-Presbyterian/
Weill Cornell Medical Center
blerman@med.cornell.edu

Allan Schwartz, MD

Chief, Division of Cardiology
NewYork-Presbyterian/
Columbia University Medical Center
as20@cumc.columbia.edu

It is expected that by the year 2020 more adults than children will need open-heart procedures to correct congenital heart defects. At NewYork-Presbyterian Hospital, cardiologists, interventional cardiologists, cardiac surgeons, and cardiac imaging specialists have come together to establish major programs in adult congenital heart disease with a focus on transitioning children seamlessly to adult care; providing the specific medical and surgical expertise needed to care for adults who have been living with heart disease since birth; and growing a new field to ensure that this population is treated by highly trained heart specialists who understand the unique aspects of adult congenital heart disease.

Adult aged patients with congenital heart disease make up a highly varied, extremely complex, and rapidly growing population. Prior to the development of novel surgical interventions in the 1960s, '70s, and '80s, many of these patients did not survive through infancy. Today, the number of adult congenital heart disease patients exceeds the number of pediatric aged patients with congenital heart disease, and continues to grow.

Each year, pediatric cardiac surgeons at the Congenital Heart Center of NewYork-Presbyterian Hospital, under the direction of **Emile A. Bacha, MD**, Chief, Division of Cardiac, Thoracic, and Vascular Surgery at NewYork-Presbyterian/Columbia, and Director, Congenital and Pediatric Cardiac Surgery at NewYork-Presbyterian, perform more than 700 cardiac operations, including some 25 heart transplants, 175 newborn heart repairs, and 100 adult congenital heart repairs.

The Congenital Heart Center is one of the first pediatric cardiology and cardiac surgery centers in the country, and one of the nation's major pediatric transplant centers, having performed a high volume of pediatric heart surgeries since the early 1970s. Today the Center has a roster of highly skilled and



Dr. Emile A. Bacha

experienced cardiovascular surgeons, including national leaders specializing in complex neonatal surgery, hybrid minimally invasive surgery, and transplant/assist devices. In particular, Dr. Bacha cites close collaboration with cardiology colleagues as integral to caring for both pediatric and adult patients with congenital heart disease.

"Our survival rates for children with CHD are about 98 percent," says Dr. Bacha, who is known for developing novel techniques to perform hybrid surgical-interventional catheter-based procedures for

many complex congenital heart defects, including hypoplastic left heart syndrome. "Patients are now thriving and growing to adulthood."

Adult congenital heart disease patients continue to need advanced care throughout the course of their lives, including imaging studies of their complex anatomy, catheter-based interventions for amelioration of residual defects and rhythm disturbances, additional surgery for repair or replacement of valves that may no longer be functioning normally, repair of residual holes in the heart, or replacement of artificial blood vessels implanted decades earlier that may become obstructed.

(continued on page 2)



NewYork-Presbyterian
Cardiology and Heart Surgery
ranks #3 in the nation.

Adult Congenital Heart Disease Comes of Age *(continued from page 1)*



Dr. Marlon S. Rosenbaum

“Adult congenital heart disease patients are very complicated,” says Dr. Bacha. “They’ve often had two, three, and four surgeries in the past – sometimes five and six. Ten years ago nobody would touch these patients. We’re benefitting now from advances in ventricle assist devices, heart transplant, intraoperative care, and ICU postoperative care. Better ways of managing patients in surgery allow us to operate on highly complex, highly difficult cases with a good success rate.”

Adult Centers Focused on CHD

“There are about 35 or more abnormalities of the heart that can occur during fetal development,” says **Marlon S. Rosenbaum, MD**, Director of the Schneeweiss Adult Congenital Heart Center at NewYork-Presbyterian/Columbia, who came to Columbia in 1987 to create one of the first adult congenital heart disease programs in the country. “Every congenital heart disease patient is different,” says Dr. Rosenbaum. “For example, someone born in the 1970s with the aorta and pulmonary artery attached to the wrong chambers would have had a baffle constructed within the upper chamber of the heart, which creates its own problems later in adulthood. Someone with the same anatomy born in 1990 would have had the two arteries returned to the appropriate chambers, a procedure that creates an entirely different set of potential issues.”

The Schneeweiss Adult Congenital Heart Disease Center recently recruited **Matthew J. Lewis, MD**, to join Dr. Rosenbaum and **Jonathan N. Ginns, MD**, in providing state-of-the-art care for these patients. Dr. Lewis serves as Director of Adult Congenital Heart Disease Research. Current research projects underway at the Schneeweiss Center include a multicenter study of adults with a failing Fontan repair for which Columbia faculty are the lead investigators; a multicenter study involving patients with a systemic right ventricle; and studies on the effect of pacing on Fontan outcome, outcome of patients who underwent pulmonary stenosis repair, and outcome of catheter ablation in patients with adult congenital heart disease.

The Cornell Center for Adult Congenital Heart Disease directed by **Harsimran S. Singh, MD**, is a collective effort among adult and pediatric specialists, offering a comprehensive approach that



Dr. Harsimran S. Singh

includes imaging experts, cardiologists, interventional cardiologists, and cardiac surgeons. “We follow adult patients with a wide spectrum of congenital heart problems,” says Dr. Singh. “These include cardiac defects often first discovered in adulthood, such as atrial septal defects and bicuspid aortic valve disease. We also see more complex birth anomalies that may have already required multiple surgeries in childhood, such as tetralogy of Fallot, transposition of the great arteries, coarctation of the aorta, and single ventricle anatomy or Fontan circulation.” Also, in conjunction with **Evelyn M. Horn, MD**, Director, Perkin Heart Failure Center, and her pulmonary hypertension team, the Cornell Center follows a large group of congenital heart patients with pulmonary hypertension and Eisenmenger’s physiology.

Surgery Across the Lifespan

“Congenital heart disease accounts for almost 1 percent of all malformations in babies,” notes **David M. Kalfa, MD, PhD**, a pediatric cardiac surgeon at NewYork-Presbyterian/Columbia. “In recent years we have had major successes in the surgical, medical, and ICU treatments of these children, and their survival has increased impressively. Now as adults, however, many require reoperations.”

As one example, Dr. Kalfa points to replacement valves and other devices that lack growth potential. “As the baby grows, the tube or valve does not, which results in a reoperation as these patients get older,” says Dr. Kalfa. “Each time it is open-heart surgery, and each time there is significant risk of complications and mortality. If you can implant a device that could grow with a child, you avoid at least two surgeries.”

Dr. Kalfa serves as the principal investigator of a multicenter research consortium that is currently developing an innovative biofunctionalized and bioresorbable polymeric valved tube. “Our aim is to achieve biodegradation of the polymer that would be replaced by new, living tissue, which would be autonomous – it would belong to the patient and would last their lifetime.”

Certain congenital heart defects, such as hypoplastic left heart syndrome, require multiple surgeries in children to correct a number of heart structures that do not fully develop. “We have to redirect

the flow of the blood so that the right ventricle is doing the work of both the pulmonary circulation and the systemic circulation,” says **Paul J. Chai, MD**, Director of Pediatric Heart Transplantation and Mechanical Assist Device Services, and Director of Congenital Heart Surgery at NewYork-Presbyterian/Weill Cornell. “The Norwood procedure is a three-stage heart surgery in which we create a ‘new’ aorta and connect it to the right ventricle and also place a tube from either the aorta or the right ventricle to the vessels supplying the lungs. This is a complex operation and probably has one of the highest risks of mortality and morbidity. We have been particularly successful with this surgery. These outcomes reflect the skill of our medical and surgical teams, as well as the excellence of our postoperative care.”


Adults who have had surgery for hypoplastic left heart syndrome as children face an uncertain future, explains Dr. Chai. “We don’t know whether the right ventricle is going to do well,” he says. “Some of these patients can have very complex anatomy as adults. When they require further surgery, whether it is a corrective surgery, valve replacement, or a transplant, their physiology and anatomy are so complicated that they should be operated on by a pediatric and congenital cardiac surgeon.”

Adult survivors of CHD face a lifelong process of medical and surgical interventions. NewYork-Presbyterian physicians agree that there is a need for having a comprehensive and seamless infrastructure in place to care for this fast-growing and challenging population of adults.

Furthermore, notes Dr. Chai, by the time the adult requires additional surgery, he or she has already undergone four or five cardiac surgeries, creating scar tissue that also presents complications. “You have to be very versatile in pediatric congenital heart surgery to be able to deal with all of these different types of patients as adults with their unique anatomy and physiology,” he says.

“Congenital bicuspid disease is a condition that we see frequently because these valves are prone to early deterioration,” says **Arash Salemi, MD**, Surgical Director, William Acquavella Heart Valve Center at NewYork-Presbyterian/Weill Cornell. “Bicuspid valves create turbulent flow and because of that the wear on them is greater than with a normal tricuspid valve. These patients present with varying degrees of symptomatic aortic stenosis down the line. The vast majority are classified Sievers 1, which represents a partial raphe between two of the three native aortic valve cusps. Less common would be a complete fusion between two of the three cusps, and the least common form would be two cusps and no evidence of a third cusp whatsoever. Bicuspid valves generally fail earlier than their tricuspid counterparts, typically in middle-age.”

In addition to correcting these challenging conditions with standard open-heart surgery, Dr. Salemi and his colleagues are pursuing alternative technologies and techniques that include the PORTICO



Dr. Paul J. Chai

resheathable transcatheter aortic valve system. “As part of the PORTICO clinical trial, we are evaluating a transcatheter, self-expanding, nitinol-based valve,” says Dr. Salemi. “It is recapturable and repositionable and is used for patients with all forms of aortic stenosis, including patients who have some varying degrees of congenital malformations. The draw of this procedure is that it’s less invasive, catheter-based, and does not require a sternotomy or the need for the heart-lung machine.”

Role of Interventional Cardiology

While medical and surgical therapies for congenital heart disease have made significant strides in recent years, at the same time the field of interventional cardiology has also experienced rapid growth.


Robert J. Sommer, MD, Director of Invasive Adult Congenital Heart Disease at NewYork-Presbyterian/Columbia, is a pediatric cardiologist who began his medical career taking care of children. Over the last 15 years, Dr. Sommer found himself transitioning to adult cardiology specifically for the management of the congenital heart disease population of patients. “Interventions have become available for closing holes, opening up valves, and fixing obstructions in large blood vessels that were congenitally malformed,” says Dr. Sommer.

A major focus of Dr. Sommer’s expertise is treating patients who have patent foramen ovale (PFO), which has been associated with various disease processes. These include paradoxical emboli causing cryptogenic strokes or other systemic arterial occlusion events, systemic hypoxemia from right-to-left shunt, decompression sickness in divers, and migraine headaches. The presenting symptom is a neurological event, either stroke or transient ischemic attack.

“PFO is a critical component of the fetal circulation,” explains Dr. Sommer. “In most babies, this flap in the heart wall closes after birth. However, there is incomplete closure in about 25 percent of babies. The vast majority of these patients will grow up and never find out that they have a PFO. But in rare cases, these patients may present with a stroke if a clot crosses from the right side of the heart to the left side, through the PFO, and reaches the brain. Additionally, there’s a significant percentage of patients with PFOs who have migraine headaches.”

At NewYork-Presbyterian/Weill Cornell, both Dr. Singh and **Geoffrey W. Bergman, MB, BS**, perform structural interventions for adults with uncorrected congenital heart defects, including PFO and atrial septal defects. The main population of patients considered for PFO closure is those with cryptogenic stroke, particularly younger patients. “Potential candidates range from teenage years up to about 60,” says Dr. Bergman. “Beyond age 60, more common causes of stroke become more predominant. However, if the workup for stroke results in no other obvious cause, then PFO must be considered.”

According to Drs. Singh and Bergman, a small percentage of patients may suffer the effect of shunting of deoxygenated blood through the PFO causing low oxygen levels in the arterial blood. “There are patients in whom changes in heart chamber stiffness,




Dr. Geoffrey W. Bergman



Dr. David M. Kalfa



Dr. Arash Salemi



Dr. Robert J. Sommer

pressure, or flow patterns can allow 'blue' or deoxygenated blood to shunt across a PFO leading to reductions in oxygen desaturation," states Dr. Singh. "One extreme, albeit rare, example of this phenomena is platypnea-orthodeoxia syndrome."

"This causes patients to become severely desaturated when they stand up," adds Dr. Bergman. "This is very limiting for patients physically and for them closure of PFO is a curative procedure."

Every patient who is a candidate for PFO closure is assessed carefully with multiple diagnostic modalities to ensure that they do not have other cardiac or vascular defects that could give rise to stroke. "They need to be evaluated for rhythm disorders, coagulation abnormalities, other structural and vascular defects, and so on," says Dr. Bergman. "We must be sure that they are truly cryptogenic and that there are no contraindications to putting a device into the patient."

"Over the past 15 or so years, PFO closure has been clinically performed using off-label devices approved for atrial septal defects," states Dr. Singh. "However, as of October 2016, the FDA has approved the Amplatzer™ PFO Occluder as the first device in the U.S. officially indicated for PFO closure in cryptogenic stroke." One pivotal study that led to this approval was the long-term data from the RESPECT trial, which shows "a 45 percent

relative risk reduction of recurrent ischemic stroke with device closure compared to medical therapy alone."

Dr. Rosenbaum and Dr. Singh note the importance of having an infrastructure in place to care for congenital heart disease patients in adulthood. "For adult patients with complex congenital heart disease, adult and pediatric cardiac specialists work together to streamline the process of transition from pediatric to adult care," says Dr. Singh. "The idea is to empower patients to achieve knowledge about their medical diagnosis and independence in their self-care. It is important for patients to understand that their pediatric doctor is not abandoning them, but rather is working together with the adult specialist as the spectrum of medical disease shifts with age. Even when they are 30 years old, there will be times when the pediatric cardiologist should be involved in clinical decision making."

"You cannot practice adult congenital heart disease in a vacuum," says Dr. Rosenbaum. "Patients are referred from other medical centers with multiple abnormalities that require correction. There are very few centers in the United States that can offer the level of multidisciplinary expertise in adult congenital heart disease that can be found at NewYork-Presbyterian."

For More Information

Dr. Emile A. Bacha • eb2709@cumc.columbia.edu
 Dr. Geoffrey W. Bergman • geb2003@med.cornell.edu
 Dr. Paul J. Chai • pac9092@med.cornell.edu
 Dr. David M. Kalfa • dk2757@cumc.columbia.edu

Reference Articles

Singh HS, Benson L, Osten M, Horlick E. Cardiac Catheterization in Adult Congenital Heart Disease. *Diagnosis and Management of Adult Congenital Heart Disease*. Ed. M.A. Gatzoulis, G.D. Webb, and P.E.F. Daubeney. Philadelphia, Elsevier, Expected in print April 2017.

Krishnamurthy G, Ratner V, Bacha E, Aspelund G. Comorbid conditions in neonates with congenital heart disease. *Pediatric Critical Care Medicine*. 2016 Aug;17(8 Suppl 1):S367-76.

Lewis M, Ginns J, Schulze C, Lippel M, Chai P, Bacha E, Mancini D, Rosenbaum M, Farr M. Outcomes of adult patients with congenital heart disease following heart transplantation: the impact of disease type, prior thoracic surgeries and bystander organ dysfunction. *Journal of Cardiac Failure*. 2016 Jul;22(7):578-82.

Sen DG, Najjar M, Yimaz B, Levasseur SM, Kalessan B, Quaegebeur JM, Bacha EA. Aiming to preserve pulmonary valve function in tetralogy of Fallot repair: comparing a new approach to traditional management. *Pediatric Cardiology*. 2016 Jun;37(5):818-25.

Dr. Marlon S. Rosenbaum • msr5@cumc.columbia.edu
 Dr. Arash Salemi • ars9001@med.cornell.edu
 Dr. Harsimran S. Singh • has9028@med.cornell.edu
 Dr. Robert J. Sommer • rs2463@cumc.columbia.edu

Kampaktsis PN, Bang CN, Wong SC, Skubas NJ, Singh HS, Voudris K, Swaminathan RJ, Kaple RK, Minutello RM, Feldman DN, Kim L, Hriljac I, Lin F, Bergman GS, Salemi A, Devereux RA. Prognostic importance of diastolic dysfunction in relation to post-procedural aortic insufficiency in patients undergoing transcatheter aortic valve replacement. *Catheterization and Cardiovascular Interventions*. 2016 May 24. [Epub ahead of print]

Blancha VL, Ratner V, Aspelund G, Chai P, Levasseur S, Krishnan U, Bacha E, Krishnamurthy G. Survival of three neonates with congenital diaphragmatic hernia and d-Transposition of the great arteries. *World Journal for Pediatric and Congenital Heart Surgery*. 2016 May 6. [Epub ahead of print]

Lee TM, Bacha EA. Copy number variants in congenital heart disease: a new risk factor impacting outcomes? *The Journal of Thoracic and Cardiovascular Surgery*. 2016 Apr;151(4):1152-53.

(continued on page 6)

A Robotic Cardiac Surgeon Grounded in the Human Touch

“When you’re in the military, particularly in war, you’re dropped in the middle of nowhere and expected to run a functioning, effective equivalent to a Level One trauma center within a week,” says **T. Sloane Guy, MD, MBA**, Director of Robotic Cardiac Surgery at NewYork-Presbyterian/Weill Cornell Medical Center. Dr. Guy served as an active-duty U.S. Army combat surgeon for nine years during a 24-year military career. Lieutenant Colonel Guy was deployed three times to Iraq and Afghanistan during which time he received the Bronze Star, Meritorious Service Medal, Combat Action Badge, and Combat Medical Badge.

“I arrived at Weill Cornell with a mission to build a robotic cardiac surgical program primarily focused on mitral valve procedures,” says Dr. Guy. His first goal was to form a working group to develop the new robotic program, bringing in representatives from perioperative care, cardiothoracic anesthesia, and profusion. “We talked about every aspect of the program in tremendous detail, from the operating room to the supplies and equipment, personnel selection, team training, and quality improvements,” says Dr. Guy. “You cannot do these operations without a dedicated team.”

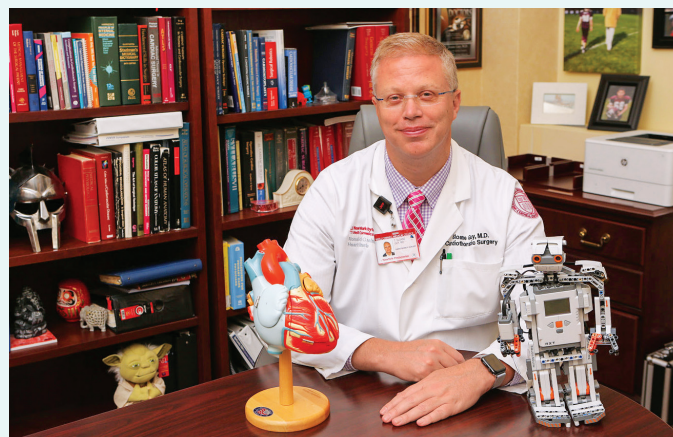The personal bonds Dr. Guy forged with his fellow soldiers, he notes, are as essential to have with your surgical team when performing complex, meticulous mitral valve repair, replacement, or another challenging cardiac surgery. His team assembled, Dr. Guy conducted mock surgeries in preparation for the launch of the robotic program. “These were complete simulations with a plastic torso and heart models performed in a fully equipped OR, including the robot, the robotic training instruments, and heart/lung machine,” says Dr. Guy. “The mock patient was also draped; we literally went through every step.”

Following the mock surgeries, Dr. Guy led what is called in the military an after action review. “We talked about what we did well, what we could have done better, and what our action items were,” he says. “I try to develop a culture of speaking freely. I told them, I needed them to be honest. Was there something I did wrong or something I could do better? Someone said, ‘Well, during this particular part of the case you were talking too much.’” To this, Dr. Guy responded, “I guess you’re right and it’s distracting.” He went on to explain to the team that during that period of time when they were working and he was waiting, he found it stress-reducing to “yack.”

“I told them that I didn’t realize the impact on them,” says Dr. Guy. “I’m willing to bet that I may be the first surgeon at Weill Cornell to ever encourage someone to basically call them out for talking too much!”

Today, nearly a year later, Dr. Guy leads a clinical team with expertise in performing a wide range of totally robotic endoscopic cardiac surgical procedures that include:

- mitral valve repair or replacement
- atrial septal defect closure
- tricuspid valve repair
- MAZE ablation for atrial fibrillation
- septal myectomy for hypertrophic cardiomyopathy
- redo cardiac surgery
- atrial myxoma resection
- coronary bypass surgery



Dr. T. Sloane Guy

After earning an MBA in Healthcare Administration from the Wharton School of Business and his MD from the University of Pennsylvania School of Medicine, Dr. Guy completed his general surgery internship at Walter Reed Army Medical Center, and his general surgery residency and cardiothoracic surgery research and clinical fellowships at Penn. Following two years as a cardiothoracic surgeon at Walter Reed, Dr. Guy was assigned to the San Francisco VA Medical Center to develop one of only two robotic and minimally invasive cardiac programs in the VA medical system at that time. Prior to joining Weill Cornell, Dr. Guy was Chief of Cardiothoracic Surgery and Robotics at Temple University.

“In the 14 years since I began performing robotic surgery, there have been four iterations of the robot,” notes Dr. Guy, who conducted research with the robotics laboratory that initially conceived and developed the da Vinci robot. “For the past two years, we have been using the da Vinci Xi®. The earlier versions involved a fairly large incision; the newest version has eight-millimeter ports.”

Da Vinci Xi employs instruments that are as nimble as a surgeon’s hands, but considerably smaller, and a 3-D camera that provides vividly clear visuals. But no matter how defined the images are or how dexterous the instruments, the surgeon cannot feel the textures and thickness of the tissue she or he is working on. “Robotic surgeons develop something I call ‘visual haptics,’” says Dr. Guy. “Your brain, calling on countless hours of human experience, makes some assumptions about the nature of the material, like heart tissue, that you are interacting with and makes an unconscious calculation about the amount of force to apply. When I do robotics, even though there is no tactile feedback, my brain is able to see the deformation of the tissue or the suture, for example, and essentially gives me a sense of how hard I’m pushing.”

Dr. Guy notes that patients value minimally invasive surgery almost as much as they value that the operation is effective. “I tell my patients my number one priority is to have them survive this operation. My number two priority is to fix their problem. Number three is to do it in the least invasive way possible. And lastly, I want to make the patient’s and family’s experience as pleasant as possible.”

For More Information

Dr. T. Sloane Guy • tsg9002@med.cornell.edu

ADVANCES IN CARDIOLOGY, INTERVENTIONAL CARDIOLOGY, AND CARDIOTHORACIC SURGERY

NewYork-Presbyterian Hospital
525 East 68th Street
New York, NY 10065
www.nyp.org

NON-PROFIT ORG.
US POSTAGE
PAID
STATEN ISLAND, NY
PERMIT NO. 169

Adult Congenital Heart Disease Comes of Age

Reference Articles (continued from page 4)

Chai PJ, George I, Nazif TM, Kalfa DM, Kodali SK, Torres AJ, Vincent JA, Leon MB, Bacha EA. Use of stented bovine pericardial valve for surgical mitral valve replacement in infants. *The Journal of Thoracic and Cardiovascular Surgery*. 2016 Mar;151(3):e51-2.

Lewis MJ, Kennedy KE, Ginns J, Crystal MA, Torres A, Vincent J, Rosenbaum MS. Procedural success and adverse events in pulmonary artery stenting: insights from the NCDR®. *Journal of the American College of Cardiology*. 2016;67(11):1327-35.

Lewis MJ, Ginns JN, Ye S, Chai P, Quaegebeur JM, Bacha E, Rosenbaum MS. Postoperative tricuspid regurgitation after adult congenital heart surgery is associated with adverse clinical outcomes. *The Journal of Thoracic and Cardiovascular Surgery*. 2016 Feb;151(2):460-65.

Singh HS, Horlick E. Chapter 29: Do We Need More PFO Trials - Hypercoagulable Syndromes, Obstructive Sleep Apnea, and Arrhythmias. *Patent Foramen Ovale*. Ed: Zahid Amin, Jonathan Tobis, Horst Sievert, and John Carroll. New York, Springer, 2015: 211-224.

Pineda AM, Mihos CG, Singla S, Santana O, Rhodes J 3rd, Sommer RJ, Rihal CS, Beohar Percutaneous closure of intracardiac defects in adults: state of the art. N1. *Journal of Invasive Cardiology*. 2015 Dec;27(12):561-72.

Kirklin JK, Huddleston CB, Egtesady P, Bacha EA. Health-related quality of life in adult survivors after the Fontan operation. *Seminars in Thoracic and Cardiovascular Surgery*. 2015 Autumn;27(3):307-8.

Chai PJ. A new approach to retrain the deconditioned left ventricle in

transposition of the great arteries. *The Journal of Thoracic and Cardiovascular Surgery*. 2015 Nov;150(5):1366-67.

Fraser CD, Bacha EA, Comas J, Sano S, Sarris GE, Tsang VT. Tetralogy of Fallot. *Seminars in Thoracic and Cardiovascular Surgery*. 2015 Summer;27(2):189-204.

Deaño RC, Shah AM, Khan Z, Bergman G, Roman MJ, Swaminathan, RV, Kim LK, Feldman DN, Minutello RM, Wong SC, Narula N, Salemi A, Singh HS. Giant coronary aneurysm diagnosed as an incidental mediastinal mass. *JACC: Cardiovascular Interventions*. 2015 Jan;8(1 Pt A):114-15.

Lewis MJ, O'Connor DS, Rozenshtien A, Ye S, Einstein AJ, Ginns JM, Rosenbaum, MS. Usefulness of magnetic resonance imaging to guide referral for pulmonary valve replacement in repaired tetralogy of Fallot. *American Journal of Cardiology*. 2014 Nov 114 (9):1406-11.

Lewis M, Ginns J, Rosenbaum M. Is systemic right ventricular function by cardiac MRI related to the degree of tricuspid regurgitation in congenitally corrected transposition of the great arteries? *International Journal of Cardiology*. 2014 April; 174 (3) 586-89.

Singh HS, Horlick E, Osten M, Benson L. Interventional cardiology in adults with congenital heart disease. *Nature Reviews. Cardiology*. 2013 Nov;10(11):662-78.

Biviano A, Garan H, Hickey K, Whang W, Dizon J, Rosenbaum M. Atrial flutter catheter ablation in adult patients with repaired tetralogy of Fallot: mechanisms and outcomes of percutaneous catheter ablation in a consecutive series. *Journal of Interventional Cardiac Electrophysiology*. 2010 Aug;28(2): 125-35.