

SPRING 2016

**George A. Cioffi, MD**

Ophthalmologist-in-Chief  
New York-Presbyterian/  
Columbia University Medical Center  
gac2126@cumc.columbia.edu

**Donald J. D'Amico, MD**

Ophthalmologist-in-Chief  
New York-Presbyterian/  
Weill Cornell Medical Center  
djd2003@med.cornell.edu



**Top Ranked Hospital in New York.  
Fifteen Years Running.**

## Noted Glaucoma Researcher Leads Clinical Trials at Columbia

Growing up in Brazil, **C. Gustavo De Moraes, MD, MPH**, saw personally the devastating effects of glaucoma not only throughout the country, but in his own family as well. Dr. De Moraes's father, a gastric surgeon, was diagnosed with glaucoma and forced to stop performing surgeries as a result of severe vision loss. "By the time I started my residency, my father had lost 90 percent of his

vision in one eye. His diagnosis led me to specialize in glaucoma," says Dr. De Moraes, Director of Clinical Trials in the Department of Ophthalmology at New York-Presbyterian/Columbia University Medical Center.

"Dr. De Moraes is the rare combination of a brilliant intellect, a skilled scientist, a gifted writer, and a compassionate physician," says **George A. Cioffi, MD**, Ophthalmologist-in-Chief at New York-Presbyterian/Columbia. A highly regarded ophthalmologist and researcher, Dr. De Moraes has published over 100 peer-reviewed papers, seven book chapters, and has been serving on the World Glaucoma Association Education Committee. He is co-author of the organization's Consensus on Medical Treatment of Glaucoma, Consensus on Glaucoma Progression, and recently co-chaired the edition of the Consensus on Glaucoma Diagnosis.

**Dr. De Moraes seeks to mitigate the global impact of glaucoma. As a volunteer with the United Nations, he has provided free screenings for glaucoma, cataracts, and refractive errors in several developing countries, where access to quality eye care is often limited.**

*(continued on page 2)*

## Anti-VEGF Treatment Research: A Sight for Sore Eyes

**Szilárd Kiss, MD**, Director of Clinical Research, Department of Ophthalmology at New York-Presbyterian/Weill Cornell Medical Center and Weill Cornell Medicine, completed his residency during a transformative time in the field. His training coincided with major developments in the understanding and application of VEGF (vascular endothelial growth factor) inhibitors to three devastating retinal diseases: age-related macular degeneration (AMD), diabetic retinopathy (DR), and retinal vein occlusion (RVO).



*Dr. Szilárd Kiss*

Exudative or wet AMD is the most advanced stage of AMD and is the most common cause of blindness in those over the age of 55, with over two million patients affected in the U.S.

"The advent of VEGF inhibitors revolutionized the way we think about these diseases," says Dr. Kiss. "I was probably in the last residency class to really see wet AMD cause blindness in just about everyone. VEGF is a central mediator of the pathology that's seen in AMD, DR, and RVO. It's not the only one, but it turns out to be the primary one. In the pre-VEGF era it was difficult to practice in the medical retina world because you couldn't offer patients

any treatment. Today, with intravitreal anti-VEGF injections, patients can expect to maintain and even improve visual function."

*(continued on page 3)*



## Noted Glaucoma Researcher Leads Clinical Trials at Columbia *(continued from page 1)*

Dr. De Moraes received his medical degree from the University of Sao Paulo School of Medicine, where he served as Chief Resident during his ophthalmology residency and remained there to pursue glaucoma and retina fellowship training. He then pursued a glaucoma research fellowship at The New York Eye and Ear Infirmary, where he was later named Chief of Glaucoma Research. After joining NewYork-Presbyterian/Columbia, he also completed a Master of Public Health degree in Biostatistics at Columbia University Mailman School of Public Health.

### Current Trials Underway

Dr. De Moraes, who serves on the Columbia University Medical Center Institutional Review Board (IRB) and has served on the Data Safety and Monitoring Board of randomized clinical trials in glaucoma, is currently overseeing the following National Institutes of Health-sponsored clinical trials at NewYork-Presbyterian/Columbia.

### Glaucomatous Damage to the Macula

In this trial, Dr. De Moraes is investigating the damage glaucoma causes to the macula and exploring innovative approaches for treating it. “While the most common form of glaucoma – open angle glaucoma – gradually narrows the peripheral visual field resulting in tunnel vision, glaucomatous damage to the macula degrades the central visual field, making activities like reading and driving extremely difficult,” says Dr. De Moraes.

The point at which the macula may become damaged and how this progression occurs has not yet been determined. Working closely with **Donald C. Hood, PhD**, Professor of Psychology and Ophthalmology at Columbia University, Dr. De Moraes seeks to fill this gap in knowledge by studying the structure and function of the macula, an innovative approach he developed here. He and his colleagues will use optical coherence tomography to visually map the structural aspects of the macula. To test functionality, they will perform visual field tests to measure the strength of the patients’ central and peripheral fields of vision and determine any vision loss. “Using these two separate tests, we intend to uncover ways of detecting the disease in its early stages and monitoring its progression more effectively,” says Dr. De Moraes.

### African Descent and Glaucoma Evaluation Study

This multicenter study, which includes the University of California-San Diego and the University of Alabama-Birmingham, recently came to Columbia University through **Jeffrey M. Liebmann, MD**, Vice Chair of Ophthalmology and Director of Glaucoma Services at Columbia. The study reunites Drs. Liebmann and De Moraes, who have previously collaborated on several clinical trials.

In this study, Dr. De Moraes is aiding investigators in identifying differences in the onset of glaucoma in populations of African and European descent. In the first phase, each of the study participants undergoes vision testing, optic nerve evaluation, and documentation of any other risk factors for developing the disease. Preliminary



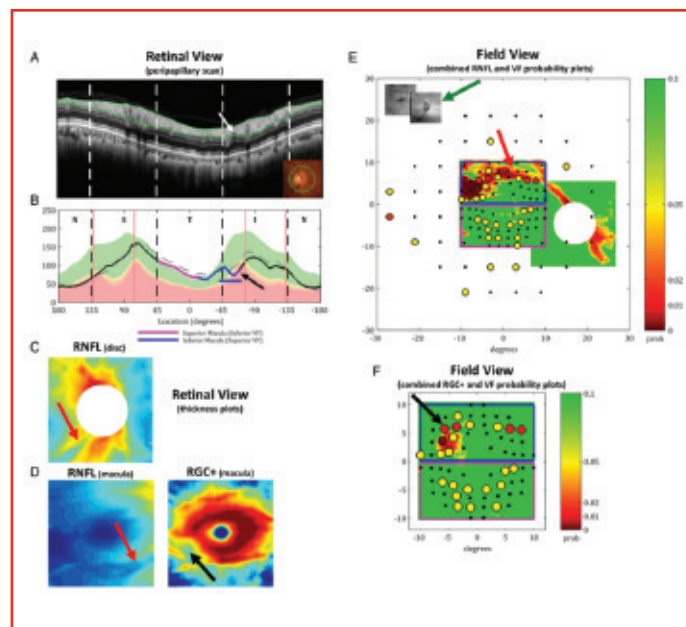
*Dr. C. Gustavo De Moraes*

findings suggest a higher prevalence of risk factors in populations of African descent, including thinner corneas, a greater risk for developing diabetes, higher blood pressure, and lower visual field test scores. Evaluating these baseline differences between the groups, the researchers hope to identify which factors might be the strongest indicators for developing glaucoma and assess how the disease impacts each racial group differently.

### Genetic Basis of Glaucoma in African Americans

An extension of the African Descent and Glaucoma Evaluation Study, this clinical trial explores the genetic basis of glaucoma. Columbia investigators are collecting blood and saliva samples and comparing that genetic data with the results from earlier

phases of the trial to pinpoint specific genetic traits or biomarkers that could help facilitate genetic diagnostic testing and enable more individualized treatments for patients.



*Dr. C. Gustavo De Moraes uses optical coherence tomography to visually map the structural aspects of the macula in his studies of glaucoma.*

### Other Clinical Trials

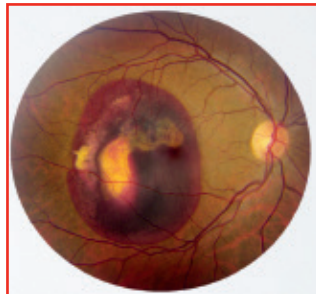In addition to the aforementioned National Institutes of Health-sponsored studies, Dr. De Moraes oversees 15 industry-sponsored clinical trials in ophthalmology. This includes breakthrough research using new treatment modalities such as gene therapy and new methods to deliver medications to the eye. Besides glaucoma, these clinical trials aim to treat diseases such as age-related macular degeneration, retinal dystrophies, keratoconus, and corneal ulcers.

*(continued on page 4)*

## Anti-VEGF Treatment Research: A Sight for Sore Eyes (continued from page 1)

While anti-VEGF agents revolutionized the outcomes of those particular retinal diseases, it comes at a cost, notes Dr. Kiss. “That cost is seen in the need for repeated injections of medication into the eye and associated injection risks such as intraocular inflammation, retinal detachment, or elevation in intraocular pressure. On average, a newly diagnosed macular degeneration patient needs about eight or nine injections every year. The question that my patients ask is, ‘For how long?’ And until recently, I could only say, ‘Forever or until something better comes along.’”

That “something better” is expected to come to fruition as the result of research in sustained delivery devices and in ocular gene therapy – avenues being studied by Dr. Kiss and his colleagues. “Our goal is to alleviate that treatment burden of eight injections a year, which causes patients to drop out of treatment far too often,” explains Dr. Kiss. “Even if you can’t reduce it to zero injections, reducing it to one or two injections a year can make a big difference in patient compliance.”



*Wet age-related macular degeneration*

### The Sustained Delivery Challenge

Discovering that VEGF plays a role in retinal diseases and, in particular, age-related macular degeneration, was indeed transformational. The next breakthrough will be in the ability to provide sustained delivery of the anti-VEGF medication. Numerous studies have revealed that the current treatment protocols – multiple injections, monthly patient monitoring, and strict retreatment guidelines – to prevent vision from deteriorating are not readily followed in clinical practice, discontinuation rates are high, and the average number of injections in patients is in the four to six range. Among these studies is an independent claims analysis of more than 10,000 newly diagnosed AMD patients analyzed by Dr. Kiss and his team.

“Data from studies by our group and other groups suggest that patients treated with anti-VEGF therapy are monitored less frequently and receive significantly fewer injections in clinical practice compared with those in major clinical trials,” says Dr. Kiss. “These less frequent dosing and follow-up strategies may, in turn, lead to inferior outcomes in visual acuity. As a result, an intense area of AMD research has focused on sustained delivery of anti-VEGF agents, both to reduce treatment burden and ideally improve visual outcome.”

Under Dr. Kiss’s leadership, the Department of Ophthalmology at Weill Cornell is the only site in the tri-state metropolitan area participating in a Genentech-sponsored, nationwide, multicenter phase II clinical trial to evaluate sustained delivery formulations of ranibizumab for neovascular age-related macular degeneration. The study will compare administration of ranibizumab via an intraocular port delivery system implant to monthly intravitreal ranibizumab injections.

“The sustained delivery device, which is not yet FDA approved, involves a reservoir used for the ranibizumab molecule,” explains

Dr. Kiss. “This reservoir can, potentially, last for six months or more. This means that you would only need to administer one or two injections a year versus eight or nine. The study, which is currently recruiting patients, will look at, in particular, the time until a participant first requires an implant refill.”

### Gene Therapy: Finding Its Role in Ocular Disorders

Avastin® (bevacizumab) – an angiogenesis inhibitor used to treat many forms of cancer – is also one of the medications used intravitreally as an off-label treatment for selected retinal diseases including wet AMD. Dr. Kiss, in collaboration with **Ronald G. Crystal, MD**, Chairman of Genetic Medicine at Weill Cornell Medicine, and his team have developed an ocular gene therapy approach using the bevacizumab molecule to alleviate the need for frequent injections.

“We think the advantage to our approach is that bevacizumab is a proven molecule...we know that it works and is being used very effectively in the clinics to treat patients,” says Dr. Kiss. “Our approach is an intravitreal one, with the delivery of our gene therapy vector similar to the current administration of bevacizumab and other anti-VEGF inhibitors. It will not require taking the patient to the operating room. The hypothesis is that if you inject the genetic material that codes for the bevacizumab molecule into the eye, then the body’s own cells will start to produce the therapeutic molecule at a constant rate for an indefinite amount of time and suppress VEGF-induced neovascularization. Theoretically, a single injection with gene therapy could replace the multitude of anti-VEGF injections for the treatment of AMD. In many ways, the eye is ideally suited for gene therapy. It is a relatively small organ that is immune privileged and has well-defined and well-characterized diseases, such as AMD, that benefit from prolonged therapy.”

The study is funded in part by the Research to Prevent Blindness Physician-Scientist Award received by Dr. Kiss and by a grant from the NIH Small Business Innovation Research program. The research is still based in the pre-clinical arena testing different vector constructs and concentrations for safety and efficacy, with the expectation of testing in humans within the next two to three years.

“While bevacizumab gene therapy is a few years away, data from phase I clinical trials for the treatment of AMD were reported for other gene therapy approaches with encouraging results for its clinical feasibility,” says Dr. Kiss. “Longer-term studies are now underway and today there are at least 15 registered clinical trials worldwide featuring intraocular gene delivery for an assortment of diseases. The initiatives in drug development and drug delivery in our field today are compelling and present us with the potential to treat diseases once thought to be untreatable. We here at Weill Cornell and at NewYork-Presbyterian are really at the forefront of this work, leading in many ways the worldwide effort to improve care for our patients with AMD, DR, and RVO.”

#### Reference Article

Seidman C, Kiss S. Gene therapy: the next frontier for treatment of acquired and inherited ocular disorders. *Retina Today*. October 2015:69-71.

#### For More Information

Dr. Szilárd Kiss • [szk7001@med.cornell.edu](mailto:szk7001@med.cornell.edu)

## Advances in Ophthalmology

NewYork-Presbyterian Hospital  
525 East 68th Street  
New York, NY 10065

[www.nyp.org](http://www.nyp.org)

NON-PROFIT ORG.  
US POSTAGE  
PAID  
STATEN ISLAND, NY  
PERMIT NO. 169

## Noted Glaucoma Researcher Leads Clinical Trials at Columbia (continued from page 2)

### Addressing Glaucoma Here and Abroad

In addition to his clinical and research efforts at NewYork-Presbyterian/Columbia, Dr. De Moraes is helping to address the global impact of glaucoma. As a volunteer with the United Nations, he has provided free screenings for glaucoma, cataracts, and refractive errors in several developing countries where access to quality eye care is often limited. He is currently working with international ophthalmology and glaucoma associations to advance global knowledge about the disease. “With over 70 million individuals suffering from glaucoma worldwide, the overall social and economic burdens that accompany the disease can prove catastrophic in terms of public well-being,” says Dr. De Moraes.

While Dr. De Moraes focuses much of his work in research, he notes that the most rewarding moments of his career are when he is able to help one of his patients. “Nothing can replace the sense of fulfillment I feel when a patient gives me a hug or a handshake and says, ‘Thank you very much, doctor.’”

### Reference Articles

Skaat A, De Moraes CG, Bowd C, Sample PA, Girkin CA, Medeiros FA, Ritch R, Weinreb RN, Zangwill LM, Liebmann JM; Diagnostic Innovations in Glaucoma Study and African Descent and Glaucoma Evaluation Study Groups. African Descent and Glaucoma Evaluation Study (ADAGES): racial differences in optic disc hemorrhage and beta-zone parapapillary atrophy. *Ophthalmology*. 2016 Apr 22. [Epub ahead of print]

Grillo LM, Wang DL, Ramachandran R, Ehrlich AC, De Moraes CG, Ritch R, Hood DC. The 24-2 visual field test misses central macular damage confirmed by the 10-2 visual field test and optical coherence tomography. *Translational Vision Science and Technology*. 2016 Apr 14;5(2):15.

Wang DL, Raza AS, De Moraes CG, Chen M, Alhadeff P, Jarukatsetphorn R, Ritch R, Hood DC. Central glaucomatous damage of the macula can be overlooked by conventional OCT retinal nerve fiber layer thickness analyses. *Translational Vision Science and Technology*. 2015 Nov 30;4(6):4.

### For More Information

Dr. C. Gustavo De Moraes • [cvd2109@cumc.columbia.edu](mailto:cvd2109@cumc.columbia.edu)