

INSIDE FALL 2008

Uterine Fibroids

2 Interventional radiologists at NewYork-Presbyterian Hospital support embolization for most patients

Contributing Faculty

2 Contact information for the faculty

RESOURCES FOR PROFESSIONALS

Webcast

"Innovations in Stroke Prevention: An Update in Carotid Stenting"

Also:

- Additional Webcasts
- CME Activities
- Medical Presentations
- Specialty Briefings
- Newsletters

Visit nyp.org/pro

Identifying Patients for Carotid Stenting

Columbia and Weill Cornell vascular specialists at NewYork-Presbyterian Hospital are at the forefront of efforts to answer one of the biggest questions in vascular medicine today: Which patients with carotid artery disease should undergo medical management, carotid stenting, or traditional surgery?

Treatments for carotid artery disease have evolved at a rapid pace; however, the optimal criteria for choosing carotid stenting or carotid endarterectomy remain under investigation. As a result, some centers have strict eligibility criteria for carotid stenting. In most US centers, stenting is used only in symptomatic patients with more than 70% stenosis and who are considered high risk for surgery. At NewYork-Presbyterian, interventional cardiologists, vascular surgeons, neuroradiologists, and neurosurgeons have been leading efforts to define the role of stenting by studying how different types of patients respond to the procedure.

The multidisciplinary vascular team at NewYork-Presbyterian enrolls most of its patients in a number of ongoing clinical trials that are expected to set the gold standard for which patients benefit from treatment employing carotid stenting. The Hospital was a major participant in CREST (Carotid Revascularization Endarterectomy Versus Stent Trial), a National Institutes of Health-sponsored study where symptomatic and asymptomatic patients are randomized to stent placement or surgery.

Approximately 2,500 patients have been enrolled nationwide, and the first results are expected in 2009-2010. The team is also enrolling patients in the ACT I (Asymptomatic Carotid Stenosis, Stenting Versus Endarterectomy Trial) that compares

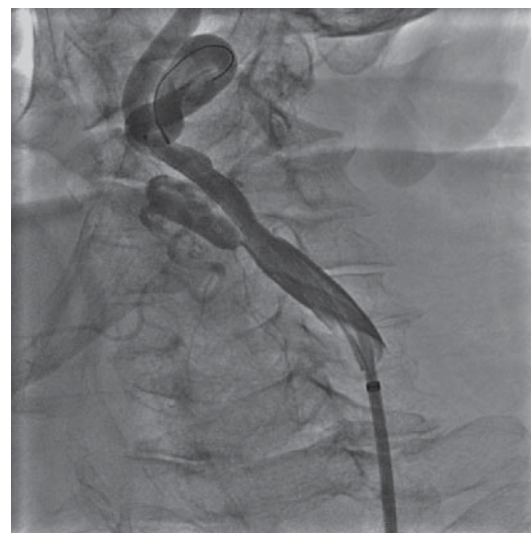

Image of a carotid stent: vascular specialists at NewYork-Presbyterian Hospital are seeking to develop patient selection criteria.

endarterectomy to stenting in patients with asymptomatic disease.

"Our results show that carotid stenting has a distinct advantage for those patients who are at increased risk for carotid surgery, including those patients with previous carotid surgery, radiation therapy to the neck, occlusion of the carotid artery on the other side of the neck, high cardiac risk, and plaques that extend far up the carotid artery," said James F. McKinsey, MD, vascular surgeon.

Interventional neuroradiologist Phil Meyers, MD, added that carotid stenting offers several advantages over traditional surgery, including being less invasive and the ability to be performed under

see **Carotid**, page 3

Multidisciplinary Team Refines Aortic Stenting

At NewYork-Presbyterian Hospital, endovascular repair of thoracic aortic and thoracoabdominal aneurysms is performed by a multidisciplinary team with extensive experience in both open and minimally invasive surgical approaches.

At NewYork-Presbyterian Hospital/Columbia University Medical Center, James McKinsey, MD, Allan Stewart, MD, and William Gray, MD, tailor care to each patient's specific circumstances. At NewYork-

Presbyterian Hospital/Weill Cornell Medical Center, meanwhile, endovascular thoracic stent repairs are conducted by John Karwowski, MD, Leonard Girardi, MD, and Arash Salemi, MD.

Open thoracic and thoracoabdominal aneurysm repairs place significant stress on the heart, lungs, kidneys, and bowels. A large incision in the chest or chest and abdomen is necessary, and the aorta has

see **Aortic**, page 4

Hospital Defines New Standard of Care for Uterine Fibroids

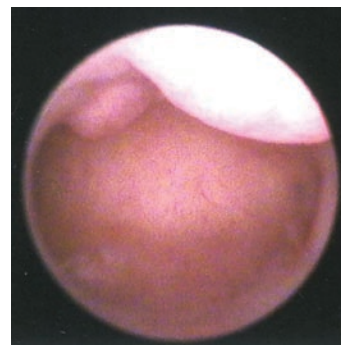
In the past several years, clinical studies have validated the use of uterine fibroid embolization (UFE) as first-line therapy for symptomatic uterine fibroids. As a result of high-level clinical trials, many of which involved Columbia and Weill Cornell researchers at NewYork-Presbyterian Hospital, “the data on UFE,” said Jonathan Susman, MD, “are better known and understood than for surgical treatments that have been around for decades.”

Symptoms related to uterine fibroids develop in 30% to 50% of women by the age of 40 years. According to Neil Khilnani, MD, “the majority of woman with fibroids are best managed conservatively with periodic follow-up visits to monitor their symptoms.” However, he added, when the symptoms affect quality of life, treatment such as hysterectomy, myomectomy, UFE, and investigational treatments such as magnetic resonance imaging–focused ultrasound ablation are indicated. David Trost, MD, noted that while UFE is an option for most patients, a few patients may still require more invasive procedures such as myomectomy or hysterectomy, which require longer hospital stays and recovery periods. “Myomectomy may not remove all fibroids whereas UFE is a global treatment,” said Dr. Susman.

In UFE, after light sedation and a local anesthetic are administered, a small catheter is inserted in the patient’s femoral artery. Using imaging guidance, the interventionalist threads the catheter into the uterine arteries and the arteries supplying the fibroids themselves. An FDA-approved embolic agent consisting of tiny microspheres, biologically inert particles made of a material similar to that used in contact lenses and smaller than grains of sand, is then injected into the arteries that supply blood to the fibroids. This selectively deprives the fibroids of their blood supply, causing them to gradually shrink.

According to Dr. Khilnani, UFE causes all fibroids to lose their blood supply 85% of the time. In most of the remaining patients, a very trivial amount of fibroid tissue remains alive. Six months after the procedure, 90% of women who undergo UFE say that their formerly heavy menstrual bleeding has decreased to a normal level, and 80% of women with pain, pressure, bloating, or discomfort in the pelvic area say that this has been largely alleviated.

Dr. Khilnani noted that the physicians at NewYork-Presbyterian were among the first in the United States to offer UFE to women with symptomatic fibroids. “We were one of the core sites for a multicenter registry to



View of a uterus with multiple submucosal fibroids.

evaluate the safety and efficacy of the procedure. Data from our group have been used to validate the success, safety, and durability of UFE. These data have been published in several landmark articles in both the interventional radiology and gynecology literature. At 5 years, the registry results demonstrate that UFE is as effective as, or more effective than, myomectomy in eliminating the symptoms of fibroids.”

“Yet despite these advantages,” noted Dr. Susman, “public awareness of UFE is limited. As physicians, we need to educate our patients about this procedure.”

Contributing faculty for this article:
**Neil Khilnani, MD; Jonathan Susman, MD;
David Trost, MD**

Contributing Faculty

The following is a list of the doctors quoted in this issue of the *NewYork-Presbyterian Vascular Newsletter*. For more information on their work, please contact them at the e-mail addresses listed.

NewYork-Presbyterian Hospital

Columbia University College of Physicians and Surgeons

Rajeev Dayal, MD

Director, Carotid Stenting
Division of Vascular Surgery
Assistant Professor of Clinical Surgery
E-mail: rd282@columbia.edu

William Gray, MD

Director, Endovascular Care
Center for Interventional Vascular Therapy
Assistant Professor of Surgery
E-mail: wg2131@columbia.edu

James F. McKinsey, MD

Interim Chief, Division of Vascular Surgery
NewYork-Presbyterian Hospital
Associate Professor of Surgery
Adjunct Associate Professor of Surgery
Weill Cornell Medical College
E-mail: jfm2111@columbia.edu

Philip M. Meyers, MD

Clinical Director, Neurovascular Services
Assistant Professor of Radiology and
Neurological Surgery
E-mail: pmm2002@columbia.edu

Allan Stewart, MD

Director, Thoracic Aortic Surgery Program
Assistant Professor of Cardiothoracic Surgery
E-mail: as2276@columbia.edu

Jonathan Susman, MD

Clinical Director, Vascular and Interventional
Radiology
Associate Clinical Professor of Radiology
E-mail: js1138@columbia.edu

Weill Cornell Medical College

Leonard Girardi, MD

Director, Aortic Surgery Program
Professor of Cardiothoracic Surgery
E-mail: lngirard@med.cornell.edu

Y. Pierre Gobin, MD

Director of Interventional Neuroradiology
Professor of Radiology in Neurological Surgery
and Neurology
E-mail: yvg2001@med.cornell.edu

John Karwowski, MD

Interim Site Chief, Division of Vascular Surgery
Assistant Professor of Surgery
Adjunct Assistant Professor of Surgery
Columbia University College of Physicians and Surgeons
E-mail: jkk2002@med.cornell.edu

Neil Khilnani, MD

Attending Radiologist
Associate Professor of Clinical Radiology
E-mail: nmkhilna@med.cornell.edu

Issam D. Moussa, MD

Director, Endovascular Services at the Cardiac
Catheterization Laboratory
Associate Professor of Medicine
E-mail: ism9003@med.cornell.edu

Arash Salemi, MD

Director, Endovascular Therapies
Department of Cardiothoracic Surgery
Assistant Professor of Cardiothoracic Surgery
E-mail: ars9001@med.cornell.edu

David Trost, MD

Associate Attending Radiologist
Associate Professor of Clinical Radiology
E-mail: datrost@med.cornell.edu

continued from **Carotid**, page 1

local anesthesia. However, results from randomized controlled trials (RCT) are mixed with regard to safety. Eleven large carotid stent studies published since 1996 report a technical success rate of more than 95%, but procedure-related stroke and mortality rates in these study populations range from 0.6% to 11% and 6-month restenosis rates are less than 5% (*Neurosurg Times* 2006;59:N6). In a single-center RCT (Sapphire, Stenting and Angioplasty with Protection in Patients at High Risk for Endarterectomy), at 1-year follow-up, carotid revascularization was repeated in fewer patients who had received stents than in those who had undergone endarterectomy (*N Eng J Med* 2004;351:1493-1501). Conversely, a large multicenter European trial (EVA-3S) was halted midway through enrollment due to the high rates of stroke in patients treated with stenting (*N Eng J Med* 2006;355:1660-1671).

Until the completion of the national RCTs, further information can be obtained from several nonrandomized, industry-sponsored trials. At last fall's Transcatheter Therapeutics Scientific Symposium, interventional cardiologist William A. Gray, MD, reported the first data from the CAPTURE (Carotid RX ACCULINK/RX ACCUNET Post-Approval Trial to Uncover Unanticipated or Rare Events) registry, which contains data on approximately 3,500 patients undergoing stenting. The results indicate that it is possible to identify favorable characteristics in patients undergoing stenting (Table).

"The most important finding from this registry is that we've been able to identify patients who do very well with this procedure," said Dr. Gray. "Patients younger than

75 years of age without symptoms appear to have a low risk for periprocedural major stroke and death, on the order of 1% to 2%. That patient population is really benefiting from this technology, at least in early studies."

"The most important finding from [the CAPTURE] registry is that we've been able to identify patients who do very well with this procedure. Patients younger than 75 years of age without symptoms appear to have a low risk for periprocedural major stroke and death, on the order of 1% to 2%. That patient population is really benefiting from this technology, at least in early studies."

—William A. Gray, MD

In addition to determining what characteristics lead to successful stent placement, there is an ongoing study to determine which patients do and do not benefit from any intervention. According to interventional cardiologist Issam Moussa, MD, the "identification, evaluation, and management of patients with asymptomatic carotid stenosis" remains a contentious issue. Proper risk stratification will identify patients who may benefit the most from carotid revascularization procedures, he added.

Columbia and Weill Cornell researchers are enrolling patients in a unique trial that may show that stenting offers neuropsychological benefits to patients with some degree of cognitive decline. Interventional radiologist Y. Pierre Gobin, MD, hypothesized that patients' cognitive skills may be diminished by reduced blood flow to the brain, which reverses once the stent is in place, after many

patients or family members of patients spoke to him about neuropsychological changes following surgery. Dr. Gobin organized the SMART (Second Manifestations of ARTerial disease) study, in which patients undergo

a battery of neuropsychological tests before and after stenting.

"We believe that in well-trained hands, carotid stenting is a safe and effective procedure," noted Rajeev Dayal, MD, vascular surgeon. "Patients typically go home within 24 hours and the risk of major stroke or mortality for patients treated at the Hospital is less than 2%. This is very much on par with carotid endarterectomy. Through collaborative efforts, we are working to understand how we can further improve patient outcomes. Our goal is to perform the most appropriate procedure for these patients. Our patients will receive the best treatment for their condition because we have access to all of the information and technology currently available."

Contributing faculty for this article:
Rajeev Dayal, MD; Y. Pierre Gobin, MD;
William Gray, MD; James F. McKinsey, MD;
Phil Meyers, MD; Issam D. Moussa, MD

Table. The CAPTURE (Carotid RX ACCULINK/RX ACCUNET Post-Approval Trial to Uncover Unanticipated or Rare Events) Registry—A Summary of Results

No. of Participants	Patient Type	30-Day Event Rate, % ^a
2,500	High-risk symptomatic and asymptomatic	5.7
2,267	Asymptomatic	4.9 ^b
n/a	80 years of age and older	8.2 ^c

^a Combined end point of death, stroke, or MI

^b Combined 30-day stroke and mortality event rate = 4.4%; 30-day stroke event rate = 3.5%

^c 30-day stroke rate = 6.6%

Note: The CAPTURE trial is an observational study required by the FDA following the market approval of the RX ACCULINK carotid stent system and RX ACCUNET distal-protection system (manufactured by Guidant) for the purpose of identifying unanticipated device malfunctions not observed in clinical trials.

continued from **Aortic**, page 1

to be temporarily clamped while the aneurysm is repaired. In contrast, endovascular stent grafting is minimally invasive and can be performed through a femoral incision, often under local anesthesia. "Thoracic aortic stent grafting can lower the risk of heart attack, breathing problems, paraplegia, and death," noted Dr. McKinsey. "And the minimally invasive procedure can dramatically shorten recovery time, compared to traditional open repair." Patients at high risk for the morbidity and mortality associated with an open repair are candidates for endovascular aortic stent-based aneurysm repair. These patients include older individuals with isolated thoracic aneurysms or individuals with advanced kidney, lung, or liver disease. "An interdisciplinary approach gives us the advantage of being able to look at the same problem from multiple directions to optimize the care of our patients," said Dr. McKinsey.

Stent graft procedures at NewYork-Presbyterian begin with computed tomography or magnetic resonance angiography imaging work-up to precisely evaluate the size and the extent of the thoracic or thoracoabdominal aneurysm. With precise measurement, the team determines where to optimally position the graft. Based on the

"Thoracic aortic stent grafting can lower the risk of heart attack, breathing problems, paraplegia, and death ... and can dramatically shorten recovery time."

—James F. McKinsey, MD

findings, the team selects the appropriate size of the graft for the particular patient. The graft is delivered into the body through the femoral artery by a catheter that is 7 to 8.9 mm in diameter.

The team at NewYork-Presbyterian also has gained valuable experience implanting grafts for complex problems of the thoracic and abdominal aorta. These include arch aneurysms with involvement of the origin of the subclavian and carotid arteries, or the aorta descending to the renal and intestinal arteries, acute complex dissections with extension into the abdominal aorta, penetrating aortic ulcers, aortic intramural hematomas, aortic arch dissections that have become aneurysmal, and traumatic tears of the aorta caused by motor vehicle accidents.

For some of these procedures, a stent graft repair may be combined with a debranching procedure, in which the intestinal or renal vessels are bypassed to maintain critical blood flow and the new debranched aorta is

excluded with a stent graft. Additionally, certain patients at high risk for open aneurysm repair and also poor anatomic candidates for endovascular stent grafting can be treated with a hybrid procedure that incorporates both open and minimally invasive approaches. Researchers at NewYork-Presbyterian are also participating in clinical trials of new stents for use in the treatment of complex aneurysms. These trials have been directed toward severely angled and short-neck abdominal aortic aneurysms as well as aortic dissections and thoracic aneurysms. Dr. McKinsey, for example, is leading a study looking at the management of juxtarenal abdominal aortic aneurysms, using a fenestrated stent graft; the stent under study has received an Investigational Device exemption from the FDA.

Contributing faculty for this article:
Leonard Girardi, MD; William Gray, MD;
John Karwowski, MD; James F. McKinsey, MD;
Arash Salemi, MD; Allan Stewart, MD



NEWYORK-PRESBYTERIAN VASCULAR

Affiliated with Columbia University College of Physicians and Surgeons and Weill Cornell Medical College

Important news from the NewYork-Presbyterian Multidisciplinary Vascular Teams—current research, clinical trials, and advances in the diagnosis and treatment of vascular disease.

NewYork-Presbyterian Hospital
525 East 68th Street
New York, NY 10065

NONPROFIT ORG.
U.S. Postage PAID
Permit No. 37
Utica, NY