NewYork-Presbyterian

2018 • Issue 1

ADVANCES IN ORTHOPEDICS

William N. Levine, MD
Orthopedic Surgeon-in-Chief
NewYork-Presbyterian/
Columbia University Medical Center
Frank E. Stinchfield Professor and Chairman of Orthopedic Surgery
Columbia University Medical Center
wnl1@cumc.columbia.edu

INSIDE THIS ISSUE

New York's #1 Hospital
17 Years in a Row

A Singular Focus on the Spine

Three years ago, NewYork-Presbyterian launched a spine hospital with its guiding principle of providing, under a single roof, a world-class center to treat the full range of conditions that can affect the spine. It was to be a spine hospital that would summon an integration of medical and surgical experts in multiple disciplines and establish programs for advanced research and education for new and seasoned physicians.

Three renowned spine surgeons – **Lawrence G. Lenke, MD**, Surgeon-in-Chief of the Daniel and Jane Och Spine Hospital; **K. Daniel Riew, MD,** Director, Cervical Spine Surgery; and **Ronald A. Lehman, Jr., MD,** Director of Degenerative and Minimally Invasive Spine Surgery – came on board to steer this singularly focused endeavor for spinal care.

Today, just three years later, the Daniel and Jane Och Spine Hospital has emerged as a destination for an increasing number of patients with complex and challenging spinal problems. Here, they find an integrated approach that unites the expertise of orthopedic spinal surgeons, neurosurgeons, physiatrists, pain management specialists, physical therapists, and specialized nursing staff.

Dr. Lawrence G. Lenke

The Spine Hospital's surgical team is trained in the most advanced, least-invasive surgical techniques, including microsurgical and endovascular options. For the most complex spinal deformity surgeries – many

(continued on page 2)

Intervertebral Discs: From Degeneration to Regeneration

Degenerative disc disease is one of the most common causes of back pain and sciatica, and most people over the age of 30 already have some degree though they may not show symptoms for many years. "Unlike osteoarthritis and other aging-related degenerative diseases, spine changes tend to start at a younger age," says **Nadeen O. Chahine, PhD,** Associate Professor of Bioengineering in Orthopedic Surgery and Biomedical Engineering at Columbia University. "Degenerative disc disease creates a socioeconomic burden because it affects people in their prime adulthood when they are pursuing careers and raising families."

> "My lab has been working on understanding causes of degeneration and whether or not the current treatment paradigm is sufficient for patients' needs."
>
> — Dr. Nadeen O. Chahine

Dr. Chahine's research looks at degeneration and regeneration of the intervertebral disc, applying tools of bioengineering, cell and tissue biomechanics, and animal physiology to study the function of the disc and disc cells, emphasizing degradation processes and inflammation.

"One area that my lab has been working on is the repair and regeneration of the intervertebral discs, trying to understand causes of degeneration and whether or not the current treatment paradigm is sufficient for patients' needs," says Dr. Chahine. "Currently, surgical approaches include spinal fusion, which does a good job in removing the source of pain, but there are associated complications. The literature

(continued on page 3)

A Singular Focus on the Spine *(continued from page 1)*

of which can be performed at only a few hospitals in the world – they employ CT imaging data to create 3D models in order to precisely plan the placement of screws and other aligning techniques before and during surgery.

Robotic technology is now being used as a tool to enhance positioning accuracy, minimize invasiveness, and reduce radiation exposure to the patient and surgical team during spine surgeries. The bone-mounted, miniature robotic system guides the accurate placement of implants, offering surgical tool guidance while leaving the actual procedure in the surgeon's hands.

"The entire Spine Hospital is set up to manage all surgical patients, from the most straightforward to the most challenging patients, from their first appointment through rehabilitation and recovery," says Dr. Lenke. "The surgical suites are designed explicitly for spinal procedures so we can perform complex procedures with attention placed on optimal patient positioning, while also providing appropriate access for anesthesia, the spinal cord/nerve root monitoring team, as well as intraoperative CT scans, X-rays, and fluoroscopy, all with an eye towards reducing complications. Patient care is coordinated with NewYork-Presbyterian's hospitalists, intensivists, cardiologists, endocrinologists, pulmonologists, and other specialists to optimize surgical outcomes and expedite recovery following surgery. You need a diverse and committed team to take care of these complex patients – ensuring the coordination of all aspects of preoperative, intraoperative, and postoperative treatment – in order to achieve the best outcomes."

A Destination for Challenging Cases

Dr. Lenke, a celebrated spine surgeon, researcher, and educator, treats patients with the most extreme and atypical deformities. Since its inception, the Spine Hospital has drawn an increased array of the most challenging cases. In fact, Dr. Lenke points to one patient who presented with one of the severest deformities he has ever seen. The 28-year-old woman had come to America from Russia to pursue an advanced degree in spite of several daunting medical challenges, including Marfan syndrome and having had two open-heart procedures.

"She was studying for her master's degree in Cleveland," says Dr. Lenke. "Cleveland Clinic, which was handling her heart issues, sent her to me to fix her spine, which had a greater than 160° scoliosis. Based on her preop condition, most hospitals would have said that she was inoperable. We were able to offer her a surgical solution that required having a complete spine reconstruction from her cervical C2 vertebrae to her pelvis. Her entire spine had to be reconstructed because it was that collapsed."

The patient's first phase of treatment involved halo traction prior to undergoing two 10-hour surgeries to correct her deformity. "Not many hospitals specialize in this type of traction," notes Dr. Lenke.

The Daniel and Jane Och Spine Hospital

- 2 operating rooms custom built for spine surgeries
- ICU beds attended by spine-specific intensivists
- Low radiation EOS X-ray imaging and 3D computed tomography
- Robotics system
- Real-time OR video feed to surgery observation rooms

"These patients need highly specialized physical, nutritional, and respiratory therapy."

Dr. Lenke then performed a vertebral column resection (VCR), an advanced procedure for which he is well known. "We used a new dual-headed screw that has one shank, which enables us to put in a temporary rod in one of the heads to hold the spine in position as we put a permanent rod in the other head," explains Dr. Lenke. "In this way, we don't have to shift out our equipment as we try to stabilize the spine during VCR procedures, which entails making the spine very unstable. It's a huge benefit. I had the opportunity to use these dual-headed screws for several months prior to her surgery, and it was extremely helpful to this patient."

Given her heart condition, the patient was very fragile from a medical perspective. "It took a variety of expertise from our medical team to help manage her postoperatively during her six-week hospitalization," adds Dr. Lenke. "She has done spectacularly well coming through surgery and is now back home in Cleveland getting ready to restart her master's program. It's a reflection of the entire team effort and the expertise that we have not only in spine surgery, but in critical care, pulmonology, and all other areas of medicine required to manage this kind of complex patient."

For More Information
Dr. Lawrence G. Lenke • ll2989@cumc.columbia.edu

Spine Study Team Wins Prestigious Whitecloud Award at IMAST

Lawrence G. Lenke, MD, Chief of the Spine Division, along with **J. Alex Sielatycki, MD**, Comprehensive Spine Fellow; **Eduardo Beauchamp, MD**, Advanced Pediatric Spinal Deformity Fellow; and **Meghan Cerpa, MPH**, Research Coordinator, have won the prestigious Thomas Whitecloud Award at the 2018 International Meeting on Advanced Spine Techniques (IMAST). The award was presented for their paper, "The Relative Curve Correction is More Important than UIV Selection for Shoulder Balance in Lenke Type 1 and 2 AIS," where Dr. Sielatycki was the first author and presenter. The Whitecloud Award is given to the best basic and clinical science papers at IMAST, one of the most important spine research meetings of the year. The meeting is sponsored by the Scoliosis Research Society and was held in Los Angeles in July.

Intervertebral Discs: From Degeneration to Regeneration *(continued from page 1)*

has shown that over time when you fuse one level of the spine it changes the overall biomechanical dynamics of the spine. Now you have adjacent discs that are seeing an abnormal mechanical environment and they begin to degenerate as well. That phenomenon – adjacent segment degeneration – can occur anywhere along the spine."

To address this complication, Dr. Chahine is investigating treatment paradigms and approaches that do not require fusion, but can maintain some physiological level of mechanical loading in a repaired disc that provides pain relief and also maintains the integrity of the spine and affected disc. Using newer technologies, including 3D printing, Dr. Chahine and her team are seeking to construct scaffolds and materials that are more in line with the native mechanical properties of the human disc.

"In the tissue engineering world, the approach has been to create a biomaterial with cellular elements from the patient's body," she says. "There have been several experiments combining chemical and mechanical factors to regenerate a replacement disc, but with limited success. Some growth happens, but the quality of the tissue, from a mechanical point of view, is far inferior to the mechanical needs of the human body."

Exploring an Alternative to the Classical Approach

"The disc itself is not a homogeneous material, but rather a composite of at least three different materials that have three different ultrastructures and mechanical function," says Dr. Chahine. "The central part of the tissue is the gelatinous nucleus pulposus that provides hydrostatic pressure support. The fluid in the disc is very important to its mechanical function. The outer part – the annulus fibrosus – is a dense collagenous tissue that provides integrity and prevents the tissue from expanding in the horizontal direction when you apply loading in the vertical direction."

Dr. Chahine is pursuing an alternative to the classical tissue engineering approach of rebuilding tissue from the ground up, as she describes it, but rather devising more novel materials and ways to combine materials together to form a scaffold that has mechanical integrity similar to native tissue.



Dr. Nadeen Chahine and her lab team are developing novel 3D printed scaffolds with optimized functional biomechanical properties for load-bearing applications.

"Perhaps we can produce a replacement that's either based out of a mechanically viable replacement, like polymer, or maybe add cells back into it and still go with the tissue engineering approach," she says. "We've been taking a novel polymer biomaterial and using a formulation that makes it viscoelastic, a kind of rubber-like material that exhibits the mechanical behavior of biological tissues. The amount of deformation that you have in the material depends on the rate that you stretch it or push on it – unlike materials such as plastics – which would not have that kind of capability."



Dr. Nadeen O. Chahine

According to Dr. Chahine, by taking different polymers and optimizing the conditions in which the researchers can print them in a 3D configuration, they can reproduce the mechanical properties that represent the nucleus pulposus and the annulus fibrosus. "We're still in the developmental bench phase of this work," she says. "We've been validating the mechanical properties of all of the parameters that go into making the disc material, optimizing those conditions, and have found the ones that are going to match the native properties well. We've also created models that simulate a human disc."

Dr. Chahine and her team have established that the material is biocompatible through their testing of cells. "We don't expect there to be any complications with toxicity when putting this material in the body," she says. "The next step is to test this tissue in an animal model or through *in vivo* studies to evaluate the responses to implanting it in the body."

While Dr. Chahine's research focus is aimed at reproducing the properties in the mechanical behavior and anatomical configurations associated with the lumbar spine, she notes there are commonalities with the cervical spine. "Perhaps some of these approaches could apply to all levels," she says. "It would just require different configuring."

Reference Articles

Shah BS, Chahine NO. Dynamic hydrostatic pressure regulates nucleus pulposus phenotypic expression and metabolism in a cell density-dependent manner. *Journal of Biomechanical Engineering.* 2018 Feb 1;140(2).

Khan AN, Jacobsen HE, Khan J, Filippi CG, Levine M, Lehman RA Jr, Riew KD, Lenke LG, Chahine NO. Inflammatory biomarkers of low back pain and disc degeneration: A review. *Annals of the New York Academy of Sciences.* 2017 Dec;1410(1):68-84.

For More Information

Dr. Nadeen O. Chahine • noc7@columbia.edu

Cervical Spinal Stenosis and Spastic Cerebral Palsy: A Call for Earlier Detection and Treatment

When **David P. Roye, Jr., MD**, Co-Director of Pediatric Orthopedics and Executive Director of the Weinberg Family Cerebral Palsy Center at NewYork-Presbyterian/Columbia University Irving Medical Center, began seeing adult patients with mild to moderate cerebral palsy, he identified a presentation pattern that gave him pause. "It became clear to me that many of these patients were being treated by physicians unaccustomed to seeing patients with cerebral palsy," says Dr. Roye. "These middle-aged patients presenting with trouble walking and increased spasticity in the legs causing more tripping and falling were being told that their symptoms were related to aging and to their cerebral palsy."



Dr. David P. Roye, Jr.

Unconvinced that the symptoms were directly related to cerebral palsy, Dr. Roye and **Joseph P. Dutkowsky, MD**, also a pediatric orthopedist with expertise in cerebral palsy, went looking for another explanation. "Making a diagnosis is difficult because these patients already have an abnormal neurologic examination," says Dr. Roye. "A typical patient with diplegia, for example, whose reflexes are hyperactive, will have abnormal findings in terms of tone and range of motion, so diagnosing a cause other than CP is challenging."

Five years ago, Dr. Roye began to screen these patients with X-rays of the cervical spine. "When we had sufficient evidence that something was going on, we would order an MRI," says Dr. Roye. "We started discovering many patients had cervical spinal stenosis. One patient from Atlanta had heard about our program and came up to see me. She had so much narrowing in the cervical spinal canal that she had ablated almost two-thirds of the space for the cord and had gone from being ambulatory to a wheelchair. She was also having bladder control problems. But nobody thought to look at her spinal cord."

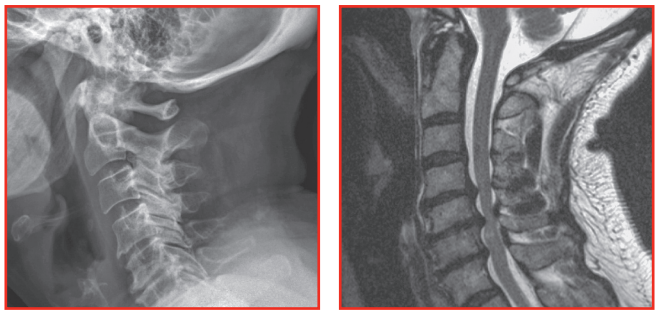

Cervical spinal stenosis in a patient with cerebral palsy as seen on X-ray and MRI

Dr. Roye referred the patient to **K. Daniel Riew, MD**, Director of Cervical Spine Surgery at the Daniel and Jane Och Spine Hospital at NewYork-Presbyterian Allen Hospital. "After surgery and rehabilitation, she went back to ambulating," says Dr. Roye.

Untreated, cervical spinal stenosis (CSS) can lead to sequelae such as loss of ambulation, upper extremity dysfunction, and incontinence. Although an association with CSS is well-recognized for athetoid/dystonic types of cerebral palsy, there is scant evidence and consists primarily of case reports. There was also little information available on CSS in patients with spastic CP.

Undertaking a 10-Year Retrospective Study

Drawing on the Weinberg Center's registry of 6,000 patients, Dr. Roye and his Columbia colleagues conducted a retrospective cohort study of 3,000 adults with cerebral palsy, from 2006 to 2016, looking for CPT (current procedural terminology) codes and ICD-10 codes associated with cervical spinal stenosis in cerebral palsy. They also reviewed demographic data, comorbidities, surgical history, and medications, comparing patients with CSS to non-CSS patients. The researchers identified 424 patients with CSS.

"It's been known in the last decade and a half that patients with dystonia are at an increased risk for cervical spinal stenosis," says Dr. Roye. "But what we found is that there is just as much increased risk in our spastic patients."

As Dr. Roye explains, many of these patients are high functioning and cognitively normal. "These individuals are teachers, lawyers, mothers, and fathers. They're out in the world moving and doing things. They are also eight times more likely than the typically developed person to have cervical spinal stenosis. And not only that, it also occurs two decades earlier."

In the general population, patients over 70 years are reported to have a higher risk of CSS, noted the researchers. However, the mean age of patients with CP presenting with CSS was much lower in their study cohort – 54.5 years of age.

"We all tend to have some degenerative change in our cervical spine as early as 35 or 40, but those degenerative changes, in and of themselves, don't cause cervical spinal stenosis," says Dr. Roye. "We think that the abnormal biomechanics of the use of the cervical spine in patients with cerebral palsy causes them to have accelerated facet arthritis and disc degeneration, which, in turn, creates stenosis."

The clinical difference in the CP population, notes Dr. Roye, is that half of them do not report neck symptoms because their stenosis is more central, pressing on the cord as opposed to pressing on the nerve roots. "The other half do report neck pain or radiating pain down the arm, the kind of pain that usually leads a person who does not have CP to seek a diagnosis," he says. "Another reason why the diagnosis is often missed or delayed for years is because patients with cerebral palsy are accustomed to being in pain and don't expect to be treated for it. I believe they ignore the symptoms they have, whereas other people might not."

(continued on page 6)

An Integrated Orthopedic and Neurosurgery Spine Fellowship

This August, the Department of Orthopedics at NewYork-Presbyterian/Columbia University Irving Medical Center welcomed both orthopedic and neurosurgery fellows into the recently integrated orthopedic and neurosurgery spine fellowship program. "This is a new and very exciting change for our program," says **Lawrence G. Lenke, MD**, Surgeon-in-Chief of the Daniel and Jane Och Spine Hospital and Co-Director of the Spine Fellowship Program.

The one-year fellowship offers training in all aspects of the cervical, thoracic, and lumbar spine from degenerative diseases and deformity to trauma injuries and tumors. Fellows perform surgical cases from complex scoliosis and kyphosis corrections with three-column osteotomies to minimally invasive procedures for cervical and lumbar disc disease. The fellows will have formal rotations with both Columbia Orthopedic and Neurosurgical spinal surgeons. Biweekly teaching sessions hosted by the faculty for fellows and residents also include a mix of lectures, case presentations, and journal discussions.

This year, notes Dr. Lenke, he and Co-Directors **Ronald A. Lehman, Jr., MD**, Director of Degenerative and Minimally Invasive Spine Surgery, and **K. Daniel Riew, MD**, Director of Cervical Spine Surgery, reviewed the nearly 120 applications received. Together, the Columbia Orthopedic and Neurosurgical spine surgeons interviewed and selected candidates for four fellowship positions.

"The top 10 individuals who we wanted to come here also listed us as their number one choice," says Dr. Lenke. "I think that level of interest is reflective of the fact that we have, quite possibly, the most highly valued spine fellowship in the country. Again, our program has been even more enhanced by adding the neurosurgeons, giving it much more diversity."

Sharing Expertise with International Colleagues

In the last three years, over 200 surgeons from 31 countries have traveled to the Daniel and Jane Och Spine Hospital to learn advanced and innovative surgical techniques from **Dr. Lawrence Lenke** and his colleagues. During their time here, they observe and participate in surgeries and benefit from clinical discussions. "Our visitors program offers an opportunity for visiting surgeons to receive advanced training that they otherwise wouldn't have in their own countries – particularly in treating patients with spinal deformities," says **Carolyn Colacicco**, Administrator.

The physicians, who spend from two weeks up to a year at the Spine Hospital, observe operations from a state-of-the-art surgical viewing room. Each of the operating rooms is equipped with a camera above the OR table and in the physician headpiece to provide two viewpoints. "They can view exactly what I'm seeing from my perspective, as well as the entire operating room," says Dr. Lenke. Each day, two visiting surgeons are also allowed direct access into the OR to enhance their educational experience.

Visitors attend a weekly conference at which faculty present and discuss each case scheduled for the week, as well as review previous surgeries. "Our visitors are also a central part of our research efforts. Many of our visiting surgeons partner with faculty to design and manage studies and become co-authors on publications during their time here," says Ms. Colacicco. Recently, one of the visitors who joined the program primarily to work with the faculty on research initiatives was nominated for the Scoliosis Research Society's Thomas Whitecloud Award for a research study, "Prevalence and Predictive Factors for Concurrent Cervical Cord Compression in Adult Spinal Deformity."

At any one time, the Spine Hospital hosts between eight and 15 surgeons who are immersed in the full complement of educational programs. "It speaks volumes about our program that these surgeons take time out of their practices and their lives to come and visit us," adds Dr. Lenke. "It's an honor to be part of that because we understand how important it is that they get the training they need to improve their surgical skills to take back to their hospital in their home countries to best treat their own patients."

Dr. Ronald A. Lehman, Jr. (front row, third from left) joins visiting physicians from Latin America and China.

NewYork-Presbyterian Hospital
622 West 168th Street
New York, NY 10032
www.nyp.org

NON-PROFIT ORG.
US POSTAGE
PAID
NEW BRUNSWICK, N.J. 08901
PERMIT NO. 1

Cervical Spinal Stenosis and Spastic Cerebral Palsy: A Call for Earlier Detection and Treatment

(continued from page 4)

In their study, the results of which were published in *Developmental Medicine and Child Neurology* in August 2017, the investigators found that of the patients with CSS, 73 percent presented with upper extremity symptoms, 70 percent with ambulation decline, 53 percent with neck pain, and 30 percent with incontinence.

Today Dr. Roye orders cervical spine X-rays for each new patient with CP over the age of 35 whether or not they have complaints. "I want to assess where they are and establish a baseline, knowing that I'll be seeing them on an annual or biannual basis and can continue to watch them," he says.

With patients in their 40s and 50s for whom he suspects having a reasonably high index of falling, worsening muscle spasms, and urinary bladder malfunction, Dr. Roye proceeds directly to an MRI. "I feel this is necessary even though many of my patients require general anesthesia to have an MRI because they can't control their movements and lie still. Our adult Radiology Department at Columbia has performed MRIs on so many of our patients that the radiologists have become very skilled in managing this population."

Due to the high prevalence of documented CSS in the adult cohort (7.5 percent), which the researchers believe is underestimated, they recommend active X-ray screening for CSS in patients with CP over age 50, and for patients with dyskinetic syndromes (i.e., athetosis) over 40 years old.

"The problem is not that we've identified a disease for which there is no treatment; we've identified a degenerative process that just isn't detected. Dr. Riew and his colleagues have very effective surgical treatments for this condition and a very high success rate," says Dr. Roye.

There are two surgical approaches often used in patients with CSS. "One is to go into the anterior cervical spine and remove the discs and then put in spacers and bone grafts to achieve fusion, motion, and to correct deformity that occurs in the cervical spine," says Dr. Roye. "In the posterior approach, the surgeon enters through the back to take the lamina off and replace it in a way that will allow the spinal cord to breathe. While it is somewhat more difficult to perform these procedures in patients who are spastic or who have a movement disorder, it absolutely can be done, and it can be life-altering for them."

Reference Article

Hung C, Linhares D, Matsumoto H, Callejo F, Kim H, Roye D, Dutkowsky J. Cervical spinal stenosis in adults with cerebral palsy – a hidden epidemic? *Developmental Medicine and Child Neurology.* 24 August 2017, Vol. 59, Issue 53.

For More Information

Dr. David P. Roye, Jr. • dpr2@cumc.columbia.edu